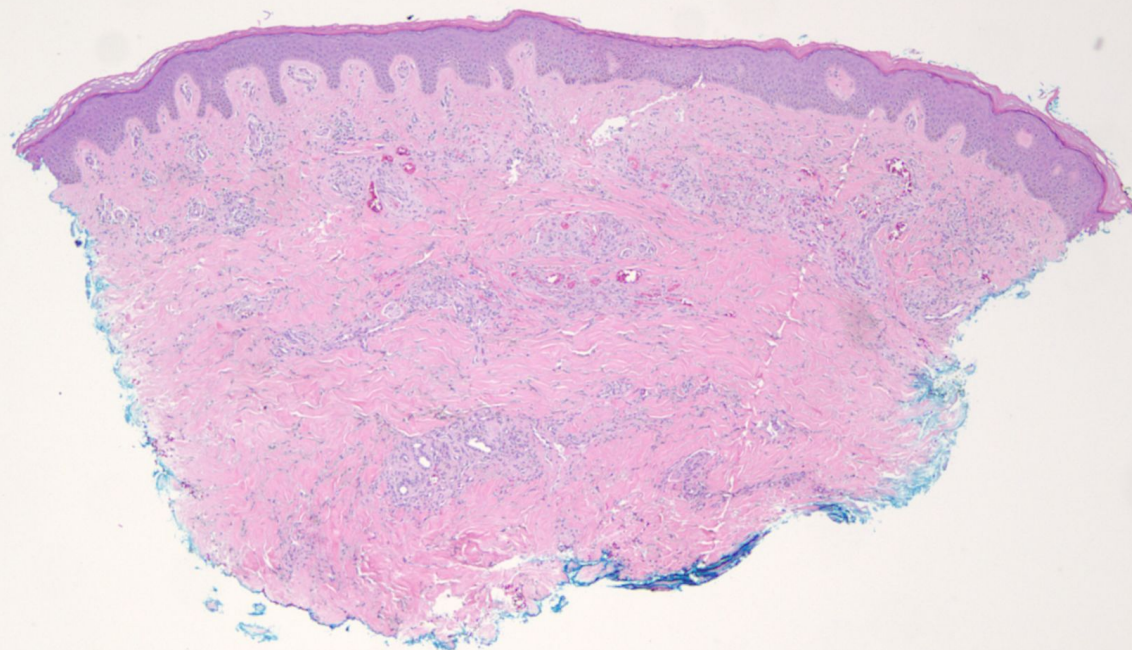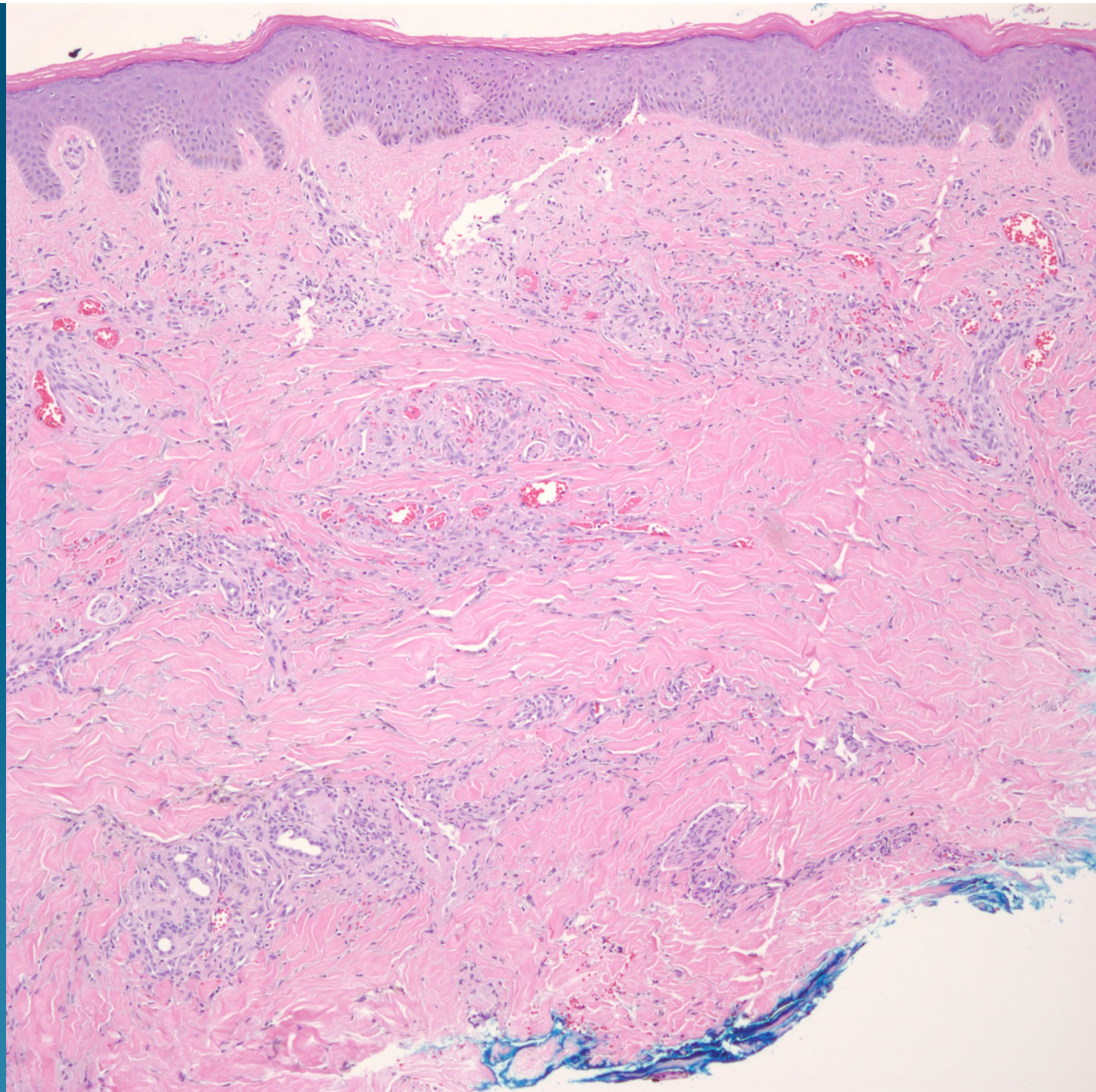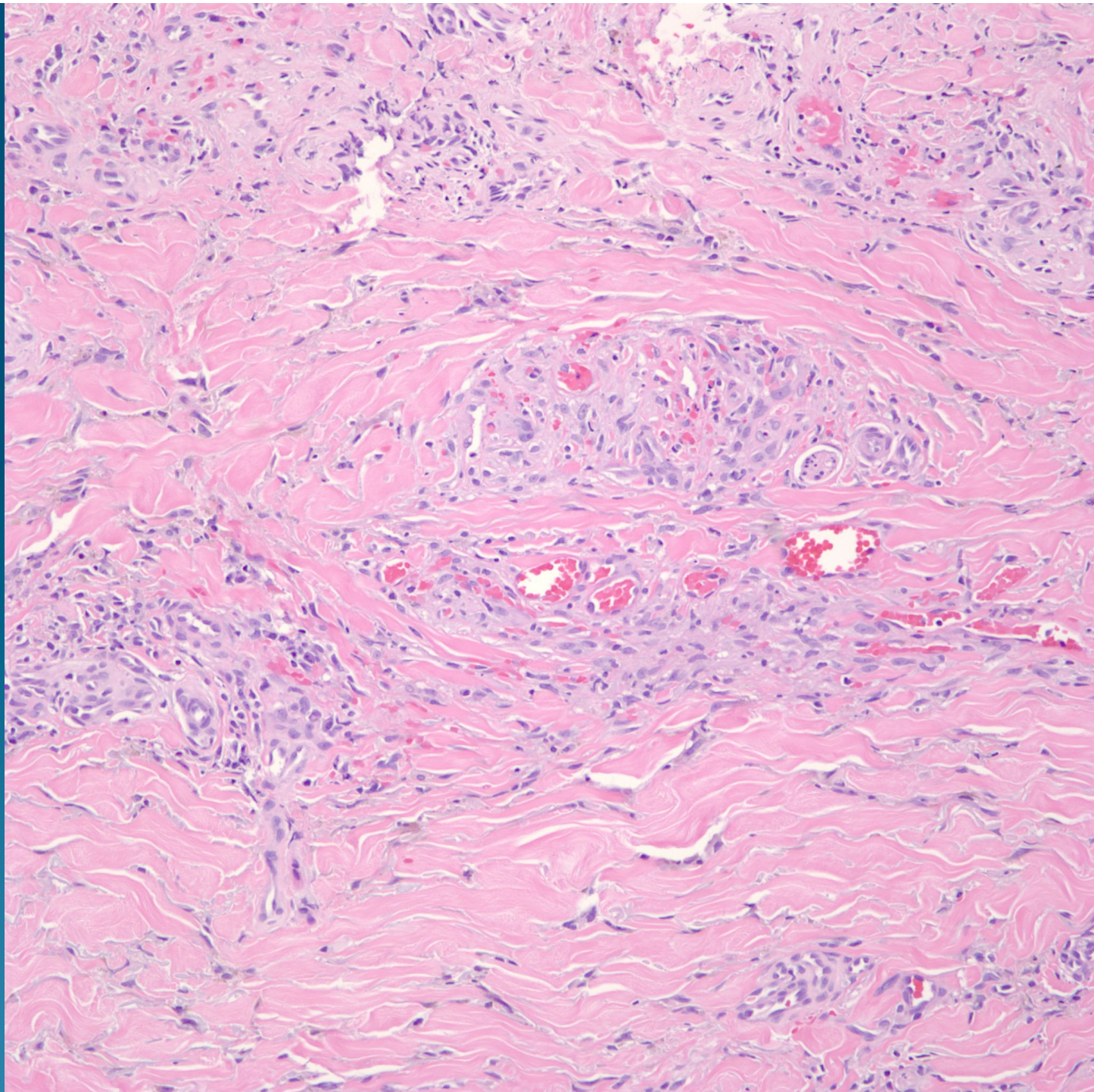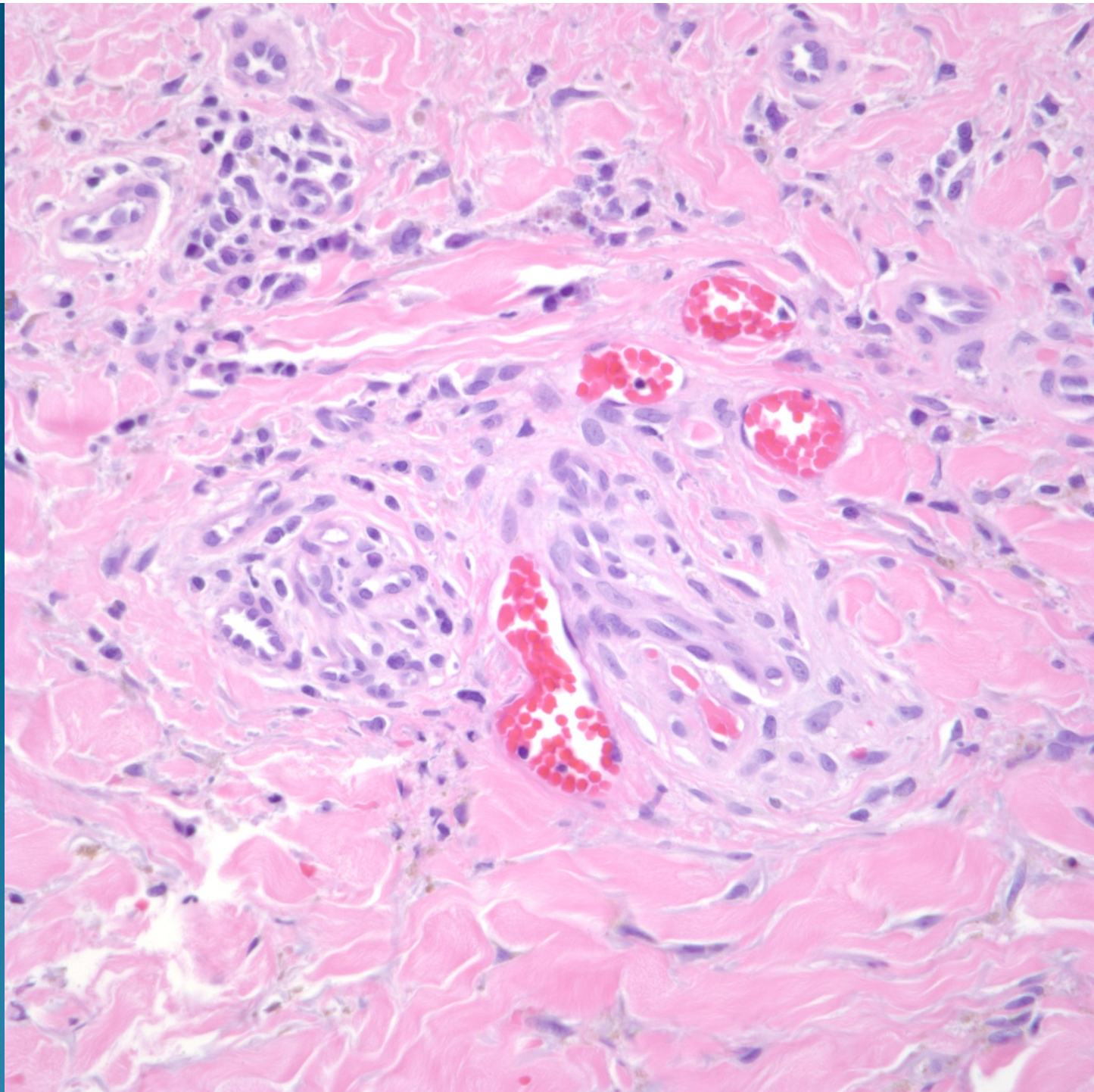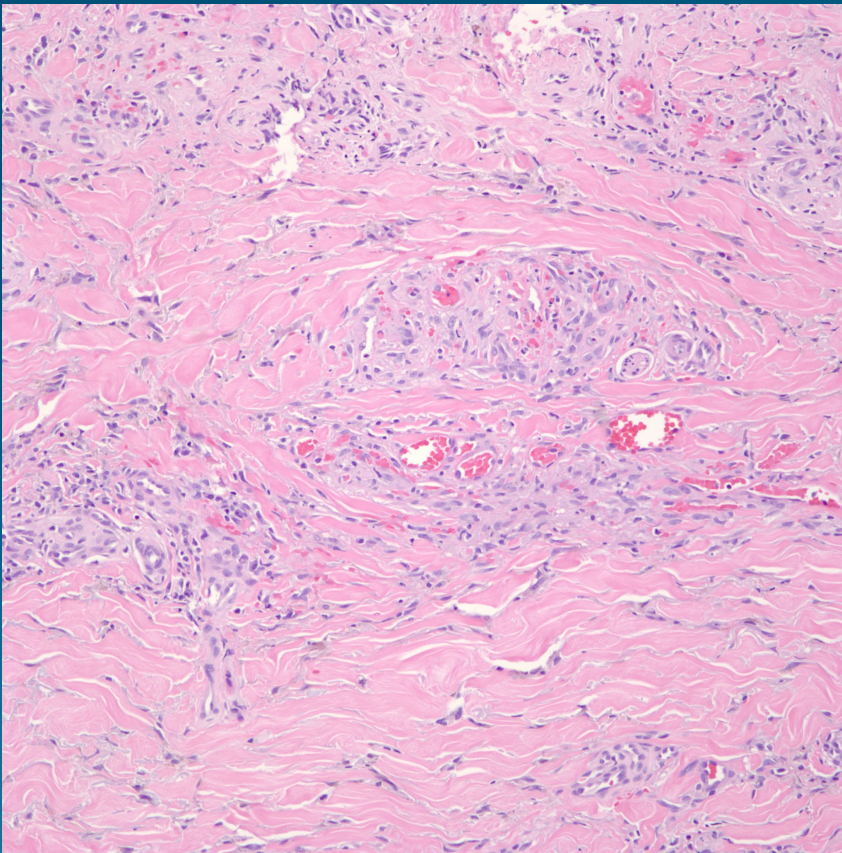


# Kaposi's Sarcoma, Plaque Stage



# Pearls



- Diffuse proliferation of vascular slit spaces with extravasated rbc's
- Scattered plasma cells and hemosiderin laden macrophages
- Hyalinized eosinophilic globules within some spindle cell cytoplasm
- Promontory sign with neoplastic vessels surrounding pre-existing vessels or adnexal structures